



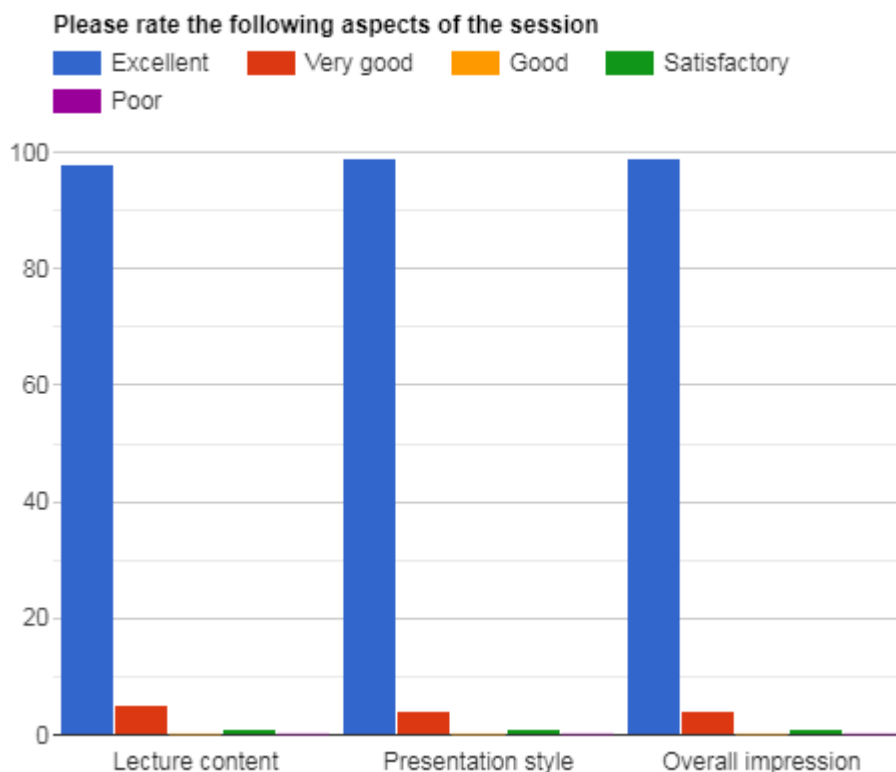
Summary Feedback

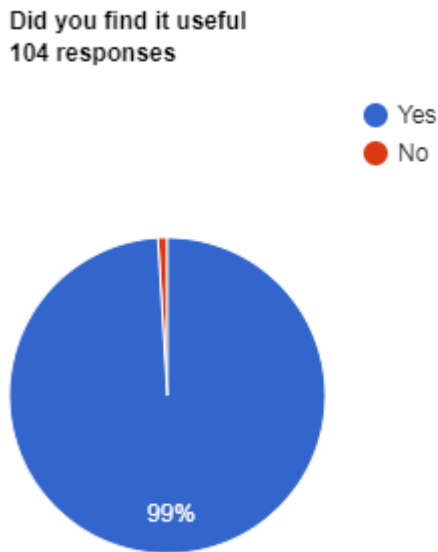
ST1 – ST4 Teaching Programme 2023

FRCR 2B Practice Viva – Interventional Radiology Cases (Session 27) (27th July 2023) Delivered By: (Muhammad Asad Hanif)

Summary Points:

- ST1-ST4 teaching programme 2023 – FRCR 2B Practice Viva Session 27: 2 hours teaching time
- Total Attendees: 312 from 34 Countries (Australia, Bahrain, Bangladesh, Canada, Egypt, Ghana, Hong Kong, India, Indonesia, Iraq, Jordan, Kenya, Kuwait, Malaysia, Mauritius, Morocco, Myanmar, Namibia, Nepal, Nigeria, Oman, Pakistan, Qatar, Saudi Arabia, South Africa, Sri Lanka, Sudan, Türkiye, UAE, UK, USA, Yemen, Zambia, Zimbabwe).
- Total feedback received from 104 participants





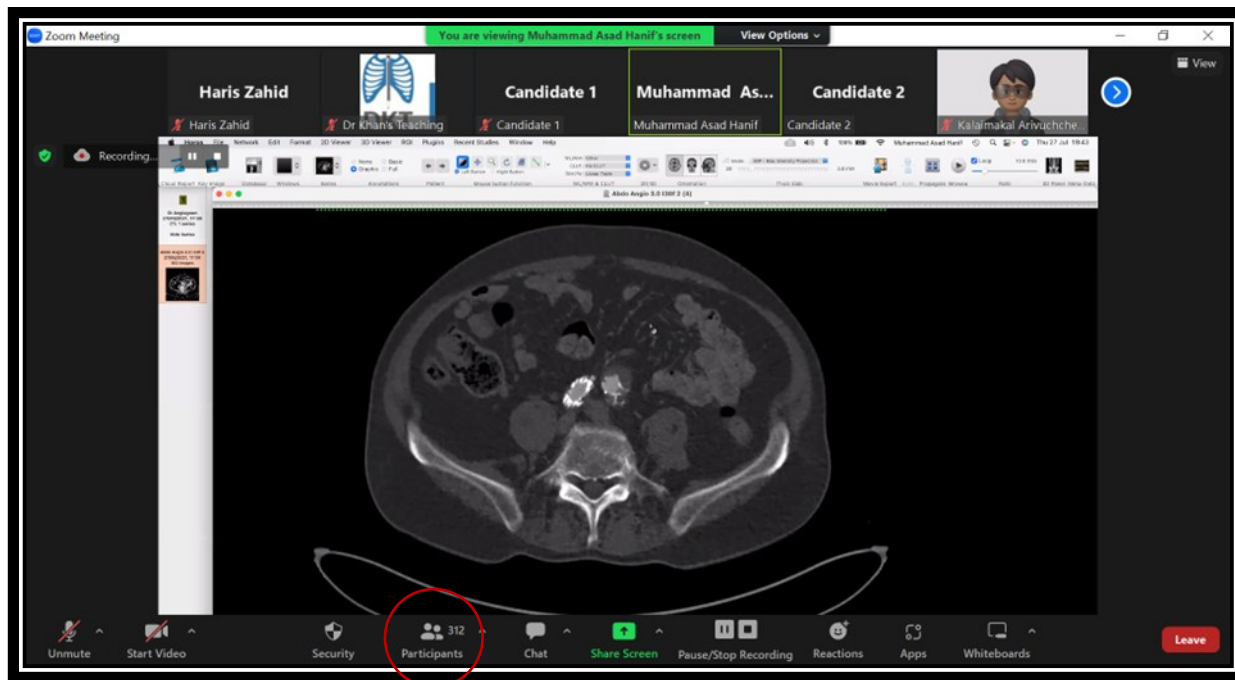
Testimonials

- Excellent session, Addressed questions very well. Kind examiner who still gave constructive feedback to candidates (UK).
- The variety of vascular disease and repeated illustration of the difference between the dissection and mural thrombus was amazing, useful tips for reporting this lesion (Saudi Arabia).
- Explanation of every point, especially regarding examination point of view was very useful (Pakistan).
- Excellent IR cases and explained patiently, cleared a lot of my concepts (Pakistan).
- Thanks a billion (Yemen).
- The viva part is good (Hong Kong).
- All aspects covered in excellent way (Pakistan).
- Very useful for exam as well as day to day practice (Sri Lanka).
- Unique cases (UK).
- Aortic aneurysm and ulcerative plaques were the most useful aspects (UK).
- Excellent explanation (Hong Kong).
- Exam cases were very valuable (Pakistan).
- Good explanation and description (India).
- Amazing session (UK).
- Case presentation was great (UK).
- Interactive (Canada).
- Emergency vascular cases were the most useful (Egypt).
- Very nice cases and informative session (UK).

FRCR 2B Practice Viva - Interventional Radiology Cases (Session 27)

- The cases were great (Nigeria).
- Useful and valuable (Yemen).
- The questions about assessing the aortic aneurysm and most of the cases were valuable (Egypt).
- All cases were amazing especially ovarian varicocele, aortocaval fistula (Egypt).
- Amazing (Egypt).
- Different cases. Method of teaching was very good (Pakistan).
- Good selection of cases (UK).
- Excellent session! (UK).
- All cases were excellent (Bahrain).
- Great cases and explanation (UK).
- Really well explained (UK).
- Clear explanations (Kenya).
- Excellent (Türkiye).
- Perfect coverage (Egypt).
- Valuable cases (UAE).
- Great session (Iraq).
- Its perfect (Pakistan).
- Great teaching (Pakistan).
- Excellent lecture (UK).
- Excellent delivery of Radiology subject (UK).
- Impressive (UK).
- Very nice session (Pakistan).
- Excellent job (Pakistan).
- Thankful (Egypt).
- Excellent, thank you so much (Egypt).
- So good and Informative (Pakistan).
- A very nice presentation (Pakistan).
- Very educative (Kenya).
- Superb (Pakistan).
- Excellent session. Clear presentation (Pakistan).
- Superb session (India).
- Very useful (UK).

FRCR 2B Practice Viva - Interventional Radiology Cases (Session 27)



=====**XX**=====**XX**=====